



Patellar instability treated with distal femoral osteotomy



Ishaan Swarup^{a,*}, Osama Elattar^b, S. Robert Rozbruch^a

^a Limb Lengthening and Complex Reconstruction Service, Hospital for Special Surgery, 535 East 70th Street, New York, NY 10021, USA

^b Orthopaedic Sports Medicine, Boston University School of Medicine, 850 Harrison Avenue, Dowling 2 North, Boston, MA 02118, USA

ARTICLE INFO

Article history:

Received 29 September 2016

Received in revised form 10 February 2017

Accepted 18 February 2017

Keywords:

Patellar instability

Genu valgum

Distal femoral osteotomy

Patient outcomes

ABSTRACT

Background: Patellar instability can cause significant disability in both pediatric and adult patients, and it is associated with several factors including genu valgum. In this study, we describe the role of a lateral opening wedge distal femoral osteotomy (DFO) combined with lateral retinacular release in addressing genu valgum with associated patellar instability. The rationale for this approach is to medialize the patellar tendon insertion and decrease the Q angle with DFO.

Methods: A consecutive series of patients were studied, and our outcomes of interest included improvements in radiographic measures and patient outcomes. Radiographic improvement was assessed using patella congruency angle (PCA), mechanical axis deviation (MAD), and lateral distal femoral angle (LDFA). Patient outcomes were assessed using Oxford Knee scores, KOOS-PS scores, VAS pain scores, and Kujala scores.

Results: We studied eight patients (10 knees) that underwent a lateral opening wedge DFO for genu valgum and patellar instability. Mean follow-up duration was 27 months. PCA improved from 30.4° lateral preoperatively to 5.7° lateral postoperatively ($p = 0.016$). Similarly, MAD improved from 33.1 mm lateral to 6.5 mm medial, and LDFA improved from 82.4° to 92.7° after surgery ($p = 0.002$). There were significant improvements in VAS pain and Kujala scores after surgery ($p < 0.05$), and a trend towards improvement in KOOS-PS scores ($p = 0.14$). The mean Oxford Knee score at follow-up was 36.25.

Conclusion: There is an important relationship between mechanical alignment and patellar instability. Lateral opening wedge DFO is an effective treatment for patellar instability in patients with genu valgum.

© 2017 Elsevier B.V. All rights reserved.

1. Introduction

Patellar instability including patella tilt, subluxation, and dislocation is a common cause of complaint and activity limitation in both pediatric and adult patients. The source of patellar instability may be secondary to congenital or developmental disorders in young patients or trauma in previously asymptomatic patients [1]. The patella tracks within the trochlea of the femur, and the medial and lateral femoral condyles provide osseous stability. A multilayer soft tissue envelope encompasses the patellofemoral joint on the medial and lateral sides [2–5], and also plays a role in patellofemoral stability. Clinically, Q angle and patellar hypermobility are used to assess patellar maltracking and represent the laterally directed force on the patella [6]. All in all, abnormalities in bony architecture such as trochlear dysplasia and patella alta; mechanical malalignment such as genu valgum; abnormal

* Corresponding author.

E-mail address: swarupi@hss.edu (I. Swarup).

geometric vectors characterized by the Q angle; and tightness of the lateral patellar soft tissues may result in patellar maltracking, instability or dislocation [1,7,8].

Several risk factors for patella instability have been described including patient characteristics such as age, ligamentous laxity, patellofemoral dysplasia, and rotational abnormalities [1,7]; as well as environmental factors such as trauma [1]. Recent reports have also suggested that valgus instability [8] and genu valgum [9,10] may be associated with patellar instability. Various treatment strategies have been described for managing patellar instability, including soft tissue realignment or reconstruction procedures, distal realignment procedures involving the tibial tubercle, and even total knee arthroplasty in cases of neglected permanent patellar dislocation [11,12]. In addition, there are a handful of case reports in the literature of distal femoral realignment procedures for the treatment of patellar dislocation. More specifically, Kwon et al. performed a medial closing wedge osteotomy of the distal femur, medial reefing and lateral retinacular release for a patient with congenital patellar dislocation, genu valgum, and lateral compartment osteoarthritis [9]. Similarly, Purushothaman et al. performed a lateral opening wedge osteotomy of the distal femur and medial patellofemoral ligament (MPFL) reconstruction for a patient with chronic post-traumatic patellar dislocation and genu valgum [10].

Despite the relationship between mechanical alignment, soft tissue dynamics, and patellar instability, there is a paucity of data regarding the clinical and radiographic outcomes after distal femoral realignment procedures for patellar instability. The current literature is limited to single case reports with limited outcomes and follow-up [9,10,13]. In this paper, we present our experience with distal femoral osteotomy (DFO) for genu valgum with associated patellar instability. We will describe clinical presentation, surgical planning, surgical technique, and radiographic and clinical outcomes after surgery. Our goal is to increase the awareness of the relationship between genu valgum and patellar instability, as well as describe a successful and reliable treatment option for this complex problem.

2. Methods

We retrospectively reviewed the clinical charts and radiographs of a consecutive series of patients with symptomatic genu valgum deformity and patellar subluxation or dislocation. All patients were treated with lateral opening wedge DFO and lateral retinacular release. The indication for surgery was symptomatic genu valgum deformity and patellar instability. Symptomatic genu valgum deformity was defined as the presence of lateral knee pain. Patellar instability was defined as a history of patellar subluxation or dislocation, or findings of patellar instability on physical exam or preoperative radiographs. Patients with advanced osteoarthritis were excluded from this study. This study was approved by our IRB and all authors vouch for the accuracy of the presented data and analyses.

2.1. Patient characteristics

Eight patients underwent a lateral opening wedge DFO between June 2010 and October 2014. A total of 10 knees were included in the analysis (six unilateral and two bilateral DFO with lateral retinacular release). Nine knees were noted to be subluxed on preoperative exam, and one knee was completely dislocated. Approximately half of all knees had evidence of patella alta as measured by the Blackburne-Peel ratio (Mean: 1.24, Range: 0.92–1.52). All knees had evidence of trochlear dysplasia, with Dejour type B being the most common (type A – three knees; type B – five knees; type C – one knee). The patient with the complete patellar dislocation underwent a concomitant tibial tubercle osteotomy; two patients underwent a tibial osteotomy for additional coronal plane deformity; and one patient underwent a proximal femoral derotational osteotomy. None of patients in our study demonstrated evidence of advanced cartilage wear on preoperative radiographs. However, two patients were noted to have a one centimeter Grade III lesion in the lateral patellar facet intra-operatively that was micro-fractured. The mean age of patients at the time of surgery was 50 (Range 23–68), and all patients were female (Table 1).

Table 1
Patient demographics and outcomes.

Patient	Age	Gender (M/F)	Laterality (L/R)	Patella position	Pre-op KOOS-PS	Post-op KOOS-PS	Pre-op VAS	Post-op VAS	Pre-op Kujala	Post-op Kujala	Oxford Knee Score
1	59	F	L	Subluxation	37	35.3	–	2	–	65	–
2	53	F	L	Subluxation	100	18.6	10	0	11	70	23
3	68	F	L	Subluxation	0	0	–	–	–	–	41
4	53	F	R	Subluxation	–	–	–	–	–	–	–
5	52	F	R	Subluxation	22	24.9	7	4	73	71	40
6	33	F	R	Dislocation	10.5	14.8	0	0	76	95	38
7	60	F	Bilateral	Subluxation	L 35.3 R 37	L 31.8 R 33.6	L 5 R 6	L 1 R 2.5	L 56 R 42	L 90 R 80	40
8	23	F	Bilateral	Subluxation	L 31.8 R 31.8	L 5.6 R 5.6	L 5.5 R 5.5	L 2 R 2	L 56 R 59	L 68 R 68	34

2.2. Surgical technique

After spinal anesthesia was administered, all patients were positioned supine on a radiolucent table. A bump was placed under the ipsilateral buttock to maintain the leg in a neutral rotational position. The entire limb was prepped and draped into the sterile field, and a sterile tourniquet was applied. A six-inch incision was made over the lateral distal femur. The iliotibial band was then incised and the vastus lateralis was elevated and dissected off the lateral intermuscular septum to expose the distal lateral femoral shaft. An oblique osteotomy was made from lateral to medial in the supracondylar femur. Approximately one centimeter of the medial cortex was left intact in order to hinge the osteotomy, and fixed with a Tomofix® locking plate (Synthes, West Chester, PA, USA). The amount of opening wedge performed of the lateral cortex was based on preoperative planning of hip to ankle standing radiographs and intraoperative assessment of mechanical axis alignment. The goal was to correct the valgus deformity. After plate fixation, the osteotomy site was grafted with allograft freeze-dried cancellous chips and grafton DBM putty. A lateral release was then performed by incising the retinaculum from the superior edge of the patella to the lateral joint line and the lateral aspect of the patella tendon. Patella tracking was checked at this point, and if there was residual patellar instability, we performed a tibial tubercle medialization osteotomy. A tibial tubercle osteotomy was needed only in one patient who had a complete patellar dislocation. Preoperative and postoperative radiographs of a patient with bilateral DFOs are shown in [Figure 1](#).

2.3. Postoperative care

Postoperatively, patients were allowed to bear 30 lb of weight for six weeks, and weight-bearing was then advanced as tolerated. All patients also began immediate range of motion (ROM) exercises of the knee using a continuous passive motion (CPM) device, and performed postoperative physical therapy for strengthening, stretching, as well as active and passive ROM of the knee. If a tibial tubercle osteotomy was performed, the knee was braced in full extension during ambulation and active extension of the knee and passive knee ROM beyond 90 degrees were restricted for the first six weeks after surgery. All patients were evaluated postoperatively with radiographs at two weeks, six weeks, three months and six months after surgery.

2.4. Outcomes of interest

Our primary outcome of interest was the patella congruency angle (PCA). In particular, we were interested in evaluating the change or improvement in PCA with surgery. In order to measure the PCA, Merchant X-rays of the knees were obtained preoperatively and postoperatively, and the sulcus angle was measured. The sulcus angle is defined as a measurement between two lines connecting the deepest point of the femoral groove to the highest points of the medial and lateral femoral condyles. The PCA was measured by drawing a line bisecting the sulcus angle, and then measuring the angle between the bisecting line and another line connecting the apex of the sulcus to the lowest aspect of the patellar ridge ([Figure 1b](#) and [d](#)). By convention, the PCA is negative since the lowest part of the patella is medial to the bisecting line, however normal values are $-6^\circ \pm 11^\circ$ [14]. We also obtained 51" full-length, standing AP radiographs preoperatively and postoperatively, and measured the mechanical axis deviation (MAD) and lateral distal femoral angle (LDFA) [15]. Normal MAD is typically 8 ± 7 mm medial to the center of the knee, and normal LDFA is typically $87.5^\circ \pm 2^\circ$ [16]. All measurements were performed by the senior author (SRR) using the methods described by Paley [15].

In addition, we assessed patient outcomes using Oxford Knee scores, Knee Injury and Osteoarthritis Outcome Score Physical Function Shortform (KOOS-PS), VAS pain scores, and Kujala questionnaire. The Oxford Knee score is a knee specific outcome, and it is used to assess outcomes after knee surgery, including osteotomies. Oxford Knee scores ranges from 0 to 48 with higher scores indicating better joint function [17]. Oxford Knee scores were obtained postoperatively in our study. The KOOS-PS is a 7-item measure of physical function and it is based on the larger KOOS survey. This survey is used to assess limitations with activities related to the patient's knee, and it has been previously used in patients with osteotomies around the knee. KOOS-PS scores range from 0 to 100 with lower scores representing no difficulty [18]. VAS pain scores ranged from 0 to 10 with lower values representing less pain. The Kujala questionnaire is a validated outcome measure for patellofemoral disorders, including patellar subluxation and dislocation. Higher Kujala scores represent less symptoms and functional limitation [19]. KOOS-PS scores, VAS pain scores, and Kujala scores were obtained postoperatively, and patients were asked to complete a preoperative and postoperative assessment of their condition. All questions were asked with the last week as the reference point, and each survey was knee-specific.

2.5. Statistical analysis

Descriptive statistics were reported in terms of means and ranges. Wilcoxon signed rank test was used to compare all preoperative and postoperative radiographic measurements. Paired t-test was used to determine any difference between preoperative and postoperative KOOS-PS scores, VAS pain scores, and Kujala scores. All analyses were conducted using SAS version 9.3 (SAS Inc., Cary, NC).

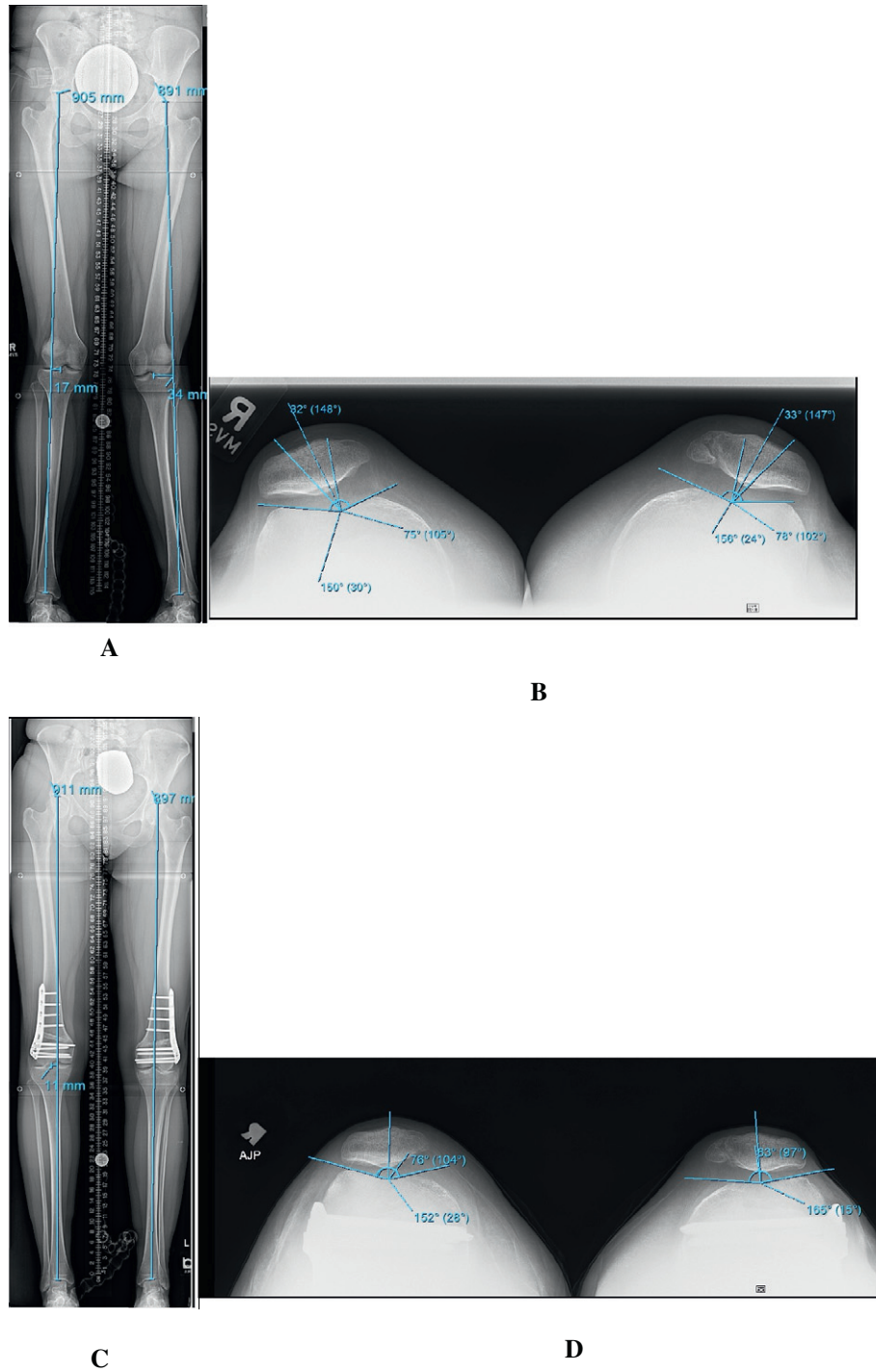


Figure 1. Case illustration: A) preoperative mechanical alignment; B) preoperative patella congruency angle; C) postoperative mechanical alignment; D) postoperative patella congruency angle.

3. Results

3.1. Patient follow-up

Mean follow-up duration was 27 months (Range: five months to 52 months). Routine bony union was noted in nine knees, and delayed union occurred in one knee. The delayed union was treated with iliac crest bone grafting, and subsequently

progressed to union. Union was assessed radiographically and clinically by the presence or absence of pain. The mean time to clinical and radiographic union was three months (Range: three months to six months). Range of motion was maintained or improved in all cases.

3.2. Radiographic outcomes

Preoperative and postoperative PCA data was available for eight knees. One knee was noted to have a complete dislocation before surgery, and preoperative PCA could not be assessed. Postoperatively, the PCA of this knee improved to 22° lateral. For the remaining knees, the mean PCA improved from 30.4° lateral to 5.7° lateral ($p = 0.016$). Preoperative and postoperative MAD and LDFA data was available for all 10 knees. The mean MAD improved from 33.1 mm lateral to 6.5 mm medial ($p = 0.002$). Similarly, the mean LDFA improved from 82.4° to 92.7° ($p = 0.002$) (Table 2).

3.3. Patient outcomes

Postoperative Oxford Knee scores were available for eight knees. The mean Oxford Knee score at follow-up was 36.25 (Range: 23–41). Preoperative and postoperative KOOS-PS scores were available for nine knees (Table 1). The mean KOOS-PS scores improved from 33.9 preoperatively to 18.9 postoperatively ($p = 0.14$). Similarly, preoperative and postoperative VAS and Kujala scores were available for seven knees. VAS pain scores improved from 5.6 pre-operatively to 1.6 post-operatively ($p = 0.01$) and Kujala scores improved from 53.3 pre-operatively to 77.4 post-operatively ($p = 0.02$). None of the patients in our study experienced subluxation or re-dislocation after surgery. Patellar instability symptoms improved as validated by our radiographic outcomes as well as the KOOS and Kujala scores.

4. Discussion

Patellar instability is a common source of discomfort and functional impairment in both children and adults. There are several factors associated with patellar instability, including mechanical alignment and genu valgum. A lateral opening wedge DFO and lateral retinacular release is an effective way to address patellar instability and correct abnormalities in mechanical alignment. Furthermore, rotational abnormalities may also contribute to patellar instability, and a derotation osteotomy may be needed to improve patellar tracking. Dickschas et al. reported significant pain relief and correction of patellar tracking with femoral derotation osteotomies in patients with torsional deformity of the femur causing anterior knee pain and patellar instability [20,21]. One patient in our study needed a femoral derotational osteotomy in conjunction with a lateral opening wedge DFO to correct all abnormalities. The derotation osteotomy and the lateral opening wedge DFO were performed at different levels of the femur. The derotation osteotomy was performed proximally with 45 degrees of external torsion correction, and fixation was achieved using an intramedullary rod. The lateral opening wedge DFO was performed distally using the technique described above.

In our study, all patients had a significant improvement in their patellar congruency and mechanical alignment after surgery (Figure 1). There was a significant improvement in VAS pain and Kujala scores postoperatively, as well as a trend towards significant improvement in KOOS-PS scores after surgery. In addition, Oxford Knee scores show that the majority of patients had satisfactory knee function after surgery, and no patients had scores consistent with severe arthritis at follow-up [17].

Clinically, patellar instability is often conceptualized and quantified using the Q angle [6]. The Q angle is dependent upon the alignment of the lower extremity, and larger Q angles result in an increased laterally-directed subluxation vector on the patella [22]. A lateral opening wedge DFO medializes the tibial tubercle, and decreases the Q angle (Figure 2). A decrease in Q angle in combination with a lateral retinacular release subsequently helps to reduce the subluxation vector on the patella and decreases patellar instability. In summary, our approach advocates for a combined lateral opening wedge DFO and lateral retinacular release that helps to address the underlying mechanical malalignment, abnormal geometric vectors, and soft tissue abnormalities.

As a whole, this study has several strengths. To begin with, there are very few studies in the literature that discuss distal femoral realignment procedures as a treatment for patellar instability. In fact, there are only a handful of case reports in the literature [9,10], and these reports focus on single patients with varying procedures, short follow-up, and limited radiographic and patient outcomes. To our knowledge, this is the largest study to report on the outcomes of lateral opening wedge DFO as a treatment for genu valgum with associated patellar instability. Furthermore, we provide a detailed discussion of our patient selection, surgical technique, radiographic measures, and patient outcomes, which will be helpful to surgeons and patients. In addition, this study

Table 2
Radiographic outcomes.

Radiographic measure	Mean	SD	Minimum	Maximum	p-Value
PCA preop (° + lateral, – medial)	30.43	16.78	14	53	0.016
PCA postop (° + lateral, – medial)	5.71	17.83	– 15	35	
MAD preop (mm + lateral, – medial)	33.10	11.48	15	51	0.002
MAD postop (mm + lateral, – medial)	– 6.50	– 4.93	– 13	0	
LDFA preop (°)	82.40	3.24	76	85	0.002
LDFA postop (°)	92.70	2.50	90	96	

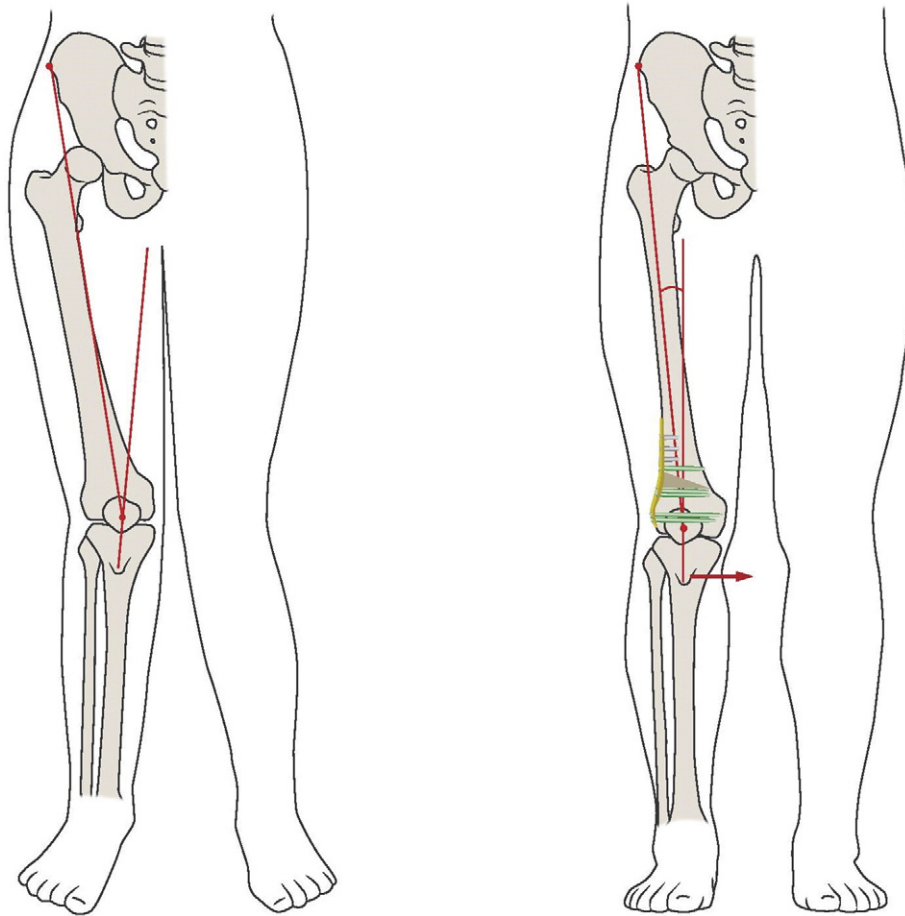


Figure 2. Improvement in Q angle and medialization of tibial tubercle after DFO.

is the first to introduce the concept of medializing the tibial tubercle with a lateral opening wedge DFO. Introducing this concept helps to further elucidate the mechanisms involved in patellar instability.

However, this study has several limitations as well. For example, this study has a small sample size and may be inadequately powered to assess an improvement in KOOS-PS scores. In addition, we did not collect preoperative Oxford Knee scores, which limits our ability to further assess improvement after surgery, and our other patient-reported outcomes were obtained postoperatively, which may introduce an element of recall bias. Regardless, this study provides detailed radiographic outcomes, and it uses validated outcome measures to assess patient outcomes after surgery. Similarly, four patients underwent concomitant osteotomies for deformity correction which may influence outcomes. However, these osteotomies were performed to address additional deformity that may have contributed to the patient's patellar instability, and our outcome measures focus on the knee. Furthermore, all patients were female and the majority of patients were over the age of 50, which limits the generalizability of our results. However, symptomatic genu valgum with associated patellar instability occurs more commonly in older female patients, and these patients continue to benefit from distal femoral realignment procedures.

Overall, it is important to assess mechanical alignment in patients with patellar instability, and genu valgum may be the cause for instability in a subset of patients. Rotational deformity of the femur may also contribute to patellar instability, and if present, the frontal and rotational deformity should be corrected. In patients with patellar instability and genu valgum, a lateral opening wedge DFO is a successful and reliable treatment option to address mechanical alignment and patellar instability. Future studies should focus on quantifying the prevalence of mechanical malalignment in patients with patellar instability, as well as report on more patients with long-term outcomes after distal femoral realignment procedures.

5. Conclusions

There is an important relationship between mechanical alignment and patellar instability, and mechanical alignment should be assessed in all patients with patellar instability. Lateral opening wedge DFO is an effective treatment option for patients with genu valgum and associated patellar instability. This procedure medializes the tibial tubercle and subsequently decreases the Q angle. All patients in this study had significant improvements in post-operative radiographic parameters and patient-reported outcomes

after surgery. Rotational deformity may also contribute to patellar instability, and if present, this deformity may need to be corrected for optimal results.

Conflict of interest

The authors have no relevant conflicts of interest.

References

- [1] Hinton RY, Sharma KM. Acute and recurrent patellar instability in the young athlete. *Orthop Clin North Am* 2003;34:385–96.
- [2] Desio SM, Burks RT, Bachus KN. Soft tissue restraints to lateral patellar translation in the human knee. *Am J Sports Med* 1998;26:59–65.
- [3] Smirk C, Morris H. The anatomy and reconstruction of the medial patellofemoral ligament. *Knee* 2003;10:221–7.
- [4] Spritzer CE. Slip sliding away: patellofemoral dislocation and tracking. *Magn Reson Imaging Clin N Am* 2000;8:299–320.
- [5] Warren LF, Marshall JL. The supporting structures and layers on the medial side of the knee: an anatomic analysis. *J Bone Joint Surg Am* 1979;61:59–62.
- [6] Sheehan FT, Derasari A, Fine FM, Brindle TJ, Alter KE. Q-angle and J-sign: indicative of maltracking subgroups in patellofemoral pain. *Clin Orthop Relat Res* 2010 Jan;468(1):266–75.
- [7] Parikh S, Noyes FR. Patellofemoral disorders: role of computed tomography and magnetic resonance imaging in defining abnormal rotational lower limb alignment. *Sports Health* Mar 2011;3(2):158–69.
- [8] Hermans K, Claes S, Bellemans J. Valgus instability as a cause for recurrent lateral patellar dislocation: a new mechanism for patellofemoral instability? *Acta Orthop Belg* 2013 Oct;79(5):495–501.
- [9] Kwon JH, Kim JI, Seo DH, Kang KW, Nam JH, Nha KW. Patellar dislocation with genu valgum treated by DFO. *Orthopedics* 2013 Jun;36(6):840–3.
- [10] Purushothaman B, Agarwal A, Dawson M. Posttraumatic chronic patellar dislocation treated by distal femoral osteotomy and medial patellofemoral ligament reconstruction. *Orthopedics* 2012 Nov;35(11):e1668–72.
- [11] Hudson J, Reddy VR, Krikler SJ. Total knee arthroplasty for neglected permanent post-traumatic patellar dislocation—case report. *Knee* 2003 Jun;10(2):207–12.
- [12] Marmor L. Total knee arthroplasty in a patient with congenital dislocation of the patella. Case report. *Clin Orthop Relat Res* Jan 1988;226:129–33.
- [13] Noda M, Saegusa Y, Kashiwagi N, Seto Y. Surgical treatment for permanent dislocation of the patella in adults. *Orthopedics* Dec 6 2011;34(12):e948–51.
- [14] Aglietti P, Insall JN, Cerulli G. Patellar pain and incongruence. I: measurements of incongruence. *Clin Orthop Relat Res* 1983;176:217–24.
- [15] Paley D, Tetsworth K. Mechanical axis deviation of the lower limbs. Preoperative planning of multiapical frontal plane angular and bowing deformities of the femur and tibia. *Clin Orthop Relat Res* 1992;280:48–64.
- [16] Paley D, Herzenberg JE, Testworth K, McKie J, Bhava A. Deformity planning for frontal and sagittal plane corrective osteotomies, 25; 1994 424–65.
- [17] Dawson J, Fitzpatrick R, Murray D, Carr A. Questionnaire on the perceptions of patients about total knee replacement. *J Bone Joint Surg Br* 1998;80-B(1):63–9.
- [18] Knee injury and osteoarthritis outcome score, Ewa Roos. Knee injury and osteoarthritis outcome score, Ewa Roos. Web. 13; Feb. 2016 (<http://www.koos.nu/>).
- [19] Kujala UM, Jaakkola LH, Koskinen SK, Taimela S, Hurme M, Nelimarkka O. Scoring of patellofemoral disorders. *Arthroscopy* 1993;9:159–63.
- [20] Dickschas J, Harrer J, Pfefferkorn R, Strecker W. Operative treatment of patellofemoral maltracking with torsional osteotomy. *Arch Orthop Trauma Surg* 2012;132(3):289–98.
- [21] Dickschas J, Harrer J, Reuter B, Schwitulla J, Strecker W. Torsional osteotomies of the femur. *J Orthop Res* 2015;33(3):318–24.
- [22] Gehrman Robin, Gozalez-Lomas Guillem. Soft-tissue injuries about the knee. In: Cannada Lisa, editor. *Orthopaedic knowledge update*. Rosemont, IL: American Academy of Orthopaedic Surgeons; 2014. p. 546–8 [Print].