

Soft Tissue Contouring at the Time of Osseointegrated Implant Reconstruction for Lower Extremity Amputation

Andrew A. Marano, MD,^{a,b} Omeed Modiri, BS,^b S Robert Rozbruch, MD,^c and David M. Otterburn, MD^{a,c}

Introduction: Patients with lower extremity amputations using a classic socket prosthesis face many challenges related to the socket-limb interface. The adaptation of osseointegration has allowed for the attachment of a prosthesis directly to bone, eliminating this interface and providing mechanical benefits. Contrary to the socket prosthesis, the osseointegrated prosthesis requires reducing and minimizing the soft tissue envelope. Studies have shown that patients who have undergone placement of these implants have high rates of reoperation for soft tissue redundancy. The purpose of our study was to evaluate complication rates and need for revisional surgery using our technique of soft tissue closure around the prosthesis at the time of implant placement.

Methods: An institutional review board–approved, retrospective chart review was performed on all patients who underwent implantation of an osseointegrated prosthesis for lower extremity amputation with concomitant plastic surgery closure at our institution during a 2-year period from June 2017 to June 2019. Patient demographics, health status descriptors, operative data, length of admission, and rates of postoperative complications were gathered from the electronic medical record and coded into a HIPAA-compliant database. Specific outcomes tracked included minor and major infection, osteomyelitis, implant failure, hematoma, seroma, delayed wound healing, and rates of reoperation and readmission.

Results: There were a total of 14 patients who underwent osseointegrated implant placement with concomitant plastic surgical coverage of the prosthesis during the study period. The average patient age was 50 years (range, 26–70 years), and average body mass index was 32.2 kg/m² (range, 19.7–44.8 kg/m²). Average follow-up time was 28 weeks (range, 10–73 weeks). There were 2 cases of local infection resolved with a course of oral antibiotics. There were no instances of infection requiring procedural intervention or hospital admission, nor any cases of osteomyelitis. Two patients required outpatient surgery for exchange of implant abutment, one required revision of a prosthesis for hardware loosening, and one required targeted muscle reinnervation of a sciatic nerve neuroma. There were no patients who required revisional surgery for soft tissue redundancy and no cases of delayed wound healing.

Conclusions: Adequate planning of incisions and soft tissue contouring is important in the care of osseointegrated patients. Plastic surgery involvement can decrease soft tissue complications and lead to improved patient outcomes.

Key Words: osseointegration, osseointegrated, osseointegrated implant, osseointegrated, prosthesis, limb amputation, extremity amputation, soft tissue, soft tissue envelope, soft tissue considerations, soft tissue management, limb reconstruction, extremity, reconstruction, amputation, socket prosthesis

(*Ann Plast Surg* 2020;85: S33–S36)

Received January 9, 2020, and accepted for publication, after revision January 28, 2020.

From the ^aNew York-Presbyterian Hospital/Weill Cornell Medical Center, Division of Plastic and Reconstructive Surgery; ^bNew York-Presbyterian Hospital/Columbia University Medical Center, Division of Plastic and Reconstructive Surgery; and ^cHospital for Special Surgery, Department of Orthopedic Surgery, New York, NY. Conflicts of interest and sources of funding: none declared.

The osseointegrated device discussed in this article is investigational and not fully Food and Drug Administration approved for this use.

Reprints: David M. Otterburn, MD, New York-Presbyterian Hospital, Weill Cornell Medical Center, 525 E 68 St, Payson 7-708, Box 115, New York, NY 10065. E-mail: dmo9004@med.cornell.edu.

Copyright © 2020 Wolters Kluwer Health, Inc. All rights reserved.

ISSN: 0148-7043/20/8501-0S33

DOI: 10.1097/SAP.0000000000002329

The prevalence of lower limb loss is of growing concern, with an increasing amount of patients living with amputation due to vascular disease, trauma, or tumors.¹ Lower extremity loss can be debilitating for patients requiring amputation, negatively impacting numerous aspects of their daily life and diminishing autonomy.^{2,3} Prosthetics have been in use to help patients return to a more active lifestyle, help restore function, and improve their overall quality of life.^{4,5} In patients with a lower extremity amputation, the current standard of care for prosthetic rehabilitation is a socket-suspended prosthesis, which involves the attachment of a prosthetic limb over a patient's residual limb using a custom designed socket. Although these prosthetics have been beneficial in supporting patients recovering from limb loss, the classic socket design is not without its shortcomings: up to a quarter of patients experience chronic wounds, perspiration issues, skin irritation, and pain.^{6–8} These problems can restrict the use of the prosthesis and impact quality of life.^{8–10}

In the last few decades, osseointegrated implants have emerged as an alternative method for adhering prosthetic components to a patient, thereby addressing the problems caused by the interface of socket prosthesis and the residual soft tissue they adhere to. Osseointegration refers to the direct fixation of an artificial implant into living bone that can stand the normal conditions of loading,¹¹ thus avoiding the pressure from bearing weight on the soft tissue around the residual limb commonly observed in traditional prosthetics. Osseointegrated bone-anchored prosthetics were originally implemented in humans for use in dental implants¹² but have later been developed for use in craniofacial deficiencies, orbital prostheses, and limb prostheses.¹³

Since the first application of bone-anchored implants for prosthetic rehabilitation of amputees, there have been several subsequent improvements in the design and surgical techniques.¹⁴ The early osseointegrated limb implants initially featured a screw fixation based on those used in dental implants but have since evolved to feature a press fitted intramedullary design to help improve long-term viability.¹⁵ In addition, the use of standardized treatment protocols guiding the implant system, surgical procedure, and rehabilitation methods has been implemented to further improve patient outcomes and reduce complications associated with osseointegrated prosthesis.^{14,16}

Despite these advances, there remains a relatively high risk of complications with osseointegrated implants, including low- or high-grade soft tissue infection, bone infection, mechanical complications, surgical revision procedures, and the need for soft tissue refashioning.^{17,18} Recent studies have shown that patients who have undergone surgery for osseointegrated implantation maintain high rates of the need for reoperation, with up to 77% of patients undergoing subsequent surgery for soft tissue–related problems.^{15,19,20} The soft tissue seal around osseointegrated implants is crucial for providing a barrier to prevent complications and also to ensure long-term viability of the implant. However, establishing a strong, permanent closure at the interface between the soft tissue and the bone-anchored implant poses its own challenges.²¹ The purpose of this study was to present our technique of soft tissue closures around osseointegrated lower extremity prostheses and review the outcomes and complication rates associated with this technique.

METHODS

A retrospective chart review was conducted on patients with a lower extremity amputation who underwent implantation of an osseointegrated prosthesis with concomitant plastic surgery closure at our institution. Hospital records were obtained from a 2-year period between June 2017 and June 2019, starting with the first osseointegrated implantation performed for limb amputation at our institution. Patients with an osseointegrated implant at the level of the femur or tibia who received soft tissue contouring at the time of surgery were included in our study. After institutional review board approval, patient data were extracted from the electronic medical record and coded into a HIPAA-compliant database.

Parameters of interest included patient demographics, health status descriptors, operative data, length of admission, and postoperative complication rates. Specific postoperative complications that were documented include minor and major infection, osteomyelitis, implant failure, hematoma, seroma, delayed wound healing, and rates of reoperation and readmission. Minor infection was defined as any clinical signs of local infection treated with outpatient oral antibiotics. Major infection was defined as purulence, abscess formation, or systemic infection requiring hospital admission, intravenous antibiotics, or surgical or procedural intervention. These outcomes were analyzed and compared with historic complication rates after osseointegrated implants for lower extremity prosthesis.

Surgical Technique

The principal goals of soft tissue reconstruction around the osseointegrated implant are relief of soft tissue redundancy and formation of a tight seal around the stoma. Preoperatively, the soft tissue

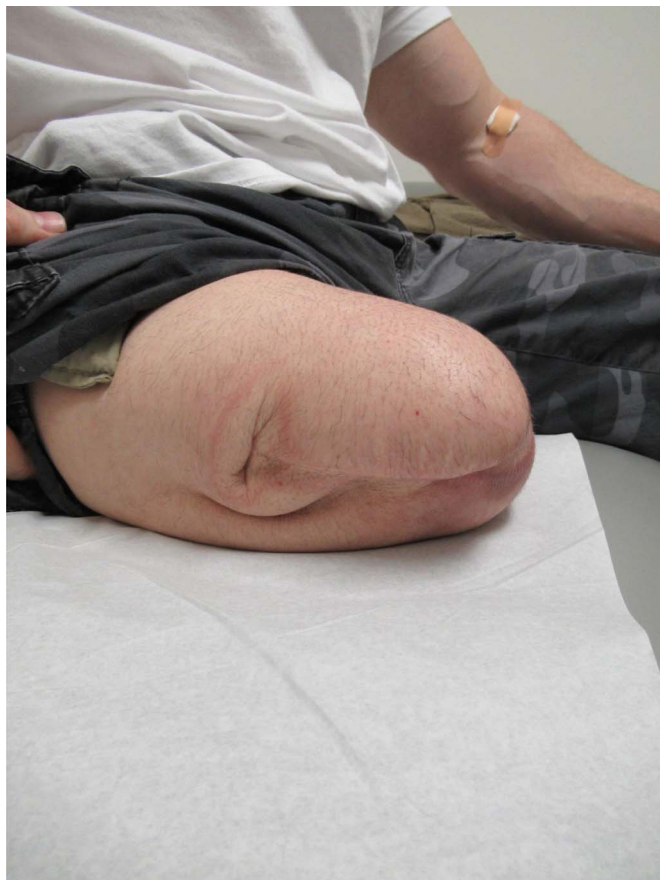

FIGURE 1. Scars and soft tissue redundancy of preoperative extremity. full color online

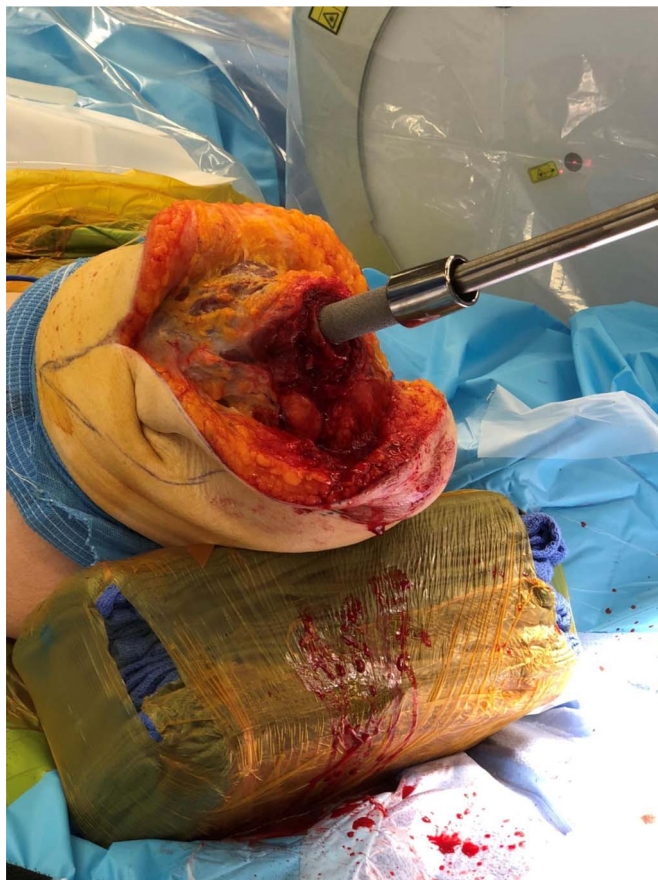

FIGURE 2. Implantation of osseointegrated prosthesis. full color online

envelope is evaluated for areas of redundancy and prior scars, and incisions are planned with the orthopedic surgery team (Fig. 1). A “fish-mouth” incision pattern is planned with a posterior skin flap that has enough length to provide an adequate skin bridge between ultimate position of the stoma and the incision.

The orthopedic surgery team exposes the distal femur or tibia and cuts it to the appropriate length, and then serial reaming is performed to create a space for the implant. Once the implant is secured, bone graft is placed at the distal bone edge (Fig. 2). The anterior and posterior musculature are dissected from the overlying soft tissue and fashioned appropriately to cover the distal bone edge without redundancy and to cover any bone graft required. A purse-string suture is then used to create a tight seal that both secure the bone graft and provide a vascularized cover of soft tissue at the implant bone interface (Fig. 3).

The skin resection is then performed with a goal of excising all excess tissue. Generally, medial and lateral incisions are made to excise both the vertical and horizontal excess of soft tissue, and it is sometimes necessary to carry these incisions far beyond the original incision to achieve adequate reduction of the soft tissue envelope. A subscarpal fat resection is then performed to remove excess subcutaneous tissue from the posterior skin flap, as bulk in this portion can prevent proper attachment of the prosthesis to the implant and/or cause ulcerations after placement of the implant. If a tourniquet was used, this should be removed to obtain the maximal resection of soft tissue. The stoma position is then marked and cut as far posterior as possible while still allowing the flap to be pulled over the implant. Progressive tension sutures may be placed as the posterior flap is advanced to offload tension from the incision line as well as obliterate dead space. A surgical drain is placed in the subcutaneous space and the incision closed in layers (Fig. 4).

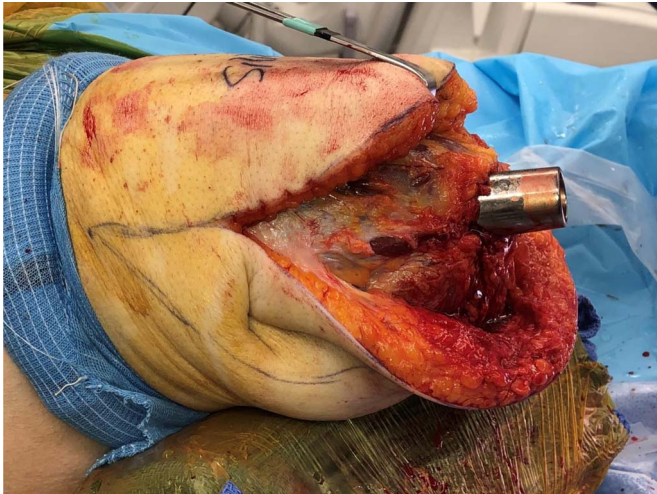


FIGURE 3. Closure of anterior and posterior musculature around implant abutment. [full color online](#)

Postoperatively, patients typically stay in the hospital for 3 to 4 days until pain is adequately controlled, and surgical drains are removed before discharge. The orthopedic surgery team dictates the schedule for load bearing. Typical postoperative results can be seen in Figure 5. It should be noted that, although the previously discussed technique represents our standard protocol, there is variety in the approach based on patient characteristics. For example, if a preceding surgery is required to clear an infection or revise an amputation, the soft tissue envelope can be thinned and tightened at that stage. If the soft tissue is adequately reduced, the bone will be immediately beneath the skin and the placement of the implant and abutment can then be done percutaneously at a second stage.

RESULTS

Over the 2-year period, there were 14 patients who underwent placement of a lower extremity osseointegrated implant with concomitant soft tissue contouring by plastic surgery. Of these patients, 12 had an amputation at the level of the femur and 2 at the level of the tibia.

The average age of patients at the time of surgery was 50 years (range, 26–70 years), and the average body mass index was 32.2 kg/m² (range, 19.7–44.8 kg/m²). Mean hospital stay was 3.9 days (range, 3–7 days), with an average follow-up time of 26 weeks (range, 10–73 weeks).

Complications

There were 3 instances of mechanical implant issues requiring outpatient reoperation—one requiring an exchange of implant abutment for broken rotation collar, one reattachment of dislodged dual taper post, and one for revision of prosthesis owing to loosening of hardware. One patient required reoperation and readmission for an open reduction and internal fixation of a fractured femur following a traumatic fall.

Two patients developed local infection that resolved with a course of oral antibiotics. There were no major infections or soft tissue complications requiring hospital admission, procedural intervention, or reoperation. There were no instances of osteomyelitis. There were no cases of soft tissue redundancy that required revisional surgery, and none of the patients experienced delayed wound healing.

DISCUSSION

The adaptation of osseointegration for use in limb amputation has greatly improved upon the shortcomings of the classic socket prostheses. Eliminating the socket-limb interface alleviates the skin breakdown and irritation, improves mechanics and control of the prosthesis, allows

for improved sensory feedback, and allows the patient to easily attach and remove the external prosthesis.²² Patients report improvements in physical functioning, bodily pain, prosthetic use, prosthetic mobility, overall health, and health-related quality of life when comparing preosseointegrated and postosseointegrated implant reconstruction.^{23,24} As the technology progresses, so does the role of the plastic surgeon. Whereas the goals of soft tissue reconstruction for socket prostheses are to provide adequate soft tissue and protective sensation, the osseointegrated prosthesis presents a new set of challenges.

One of the primary concerns with osseointegrated prostheses and perhaps what hindered earlier adaptation of the technology is the risk for deep space infection and osteomyelitis. The implant is both percutaneous and osseointegrated, thus creating a theoretical passage from the external environment to bone, particularly as nonvascularized bone graft is used. The largest series to date evaluating infection risk reports an osteomyelitis rate of approximately 20% and a gradual increase in the rate over the 10-year period observed.²⁵ This series was published by the group that first described osseointegration for limb amputation, and the technology has since progressed. Long-term data using the most recently developed press-fit prosthesis, however, have yet to be established. To best mitigate the risk of infection, we strive to provide a tight, well-vascularized, multilayered closure at the stoma. This is accomplished by using anterior and posterior musculature to provide circumferential coverage, secured over the bone/implant interface using a purse-string suture. When advancing the posterior skin flap to its final position, the aperture is designed to be smaller than the diameter of the implant so that it must be stretched around the post and then allowed to recoil. This must be performed without the tourniquet in place to allow for tight advancement of the posterior skin flap, which will house the stoma incision. The tight fit of the contoured skin and soft tissue is mandatory to prevent possible impingement on the adaptor and to minimize the soft tissue interfacing with the metal, which can lead to irritation, inflammation, and possible infection. Although our series includes no cases of osteomyelitis, our observations are limited to 1 year of follow-up. The effect of these measures will not be evident until long-term data are available.

The most common cause for reoperation in this patient population is the fit and viability of the soft tissues. An early series reports approximately 38% rate of revisional surgery for problems at the stoma, with 2 patients requiring implant removal after chronic soft tissue problems at the dermal interface.¹⁹ A follow-up study from the same group showed that the initial cohort had increased to a 77% rate of soft tissue-related reoperation but that, after advances in implant design and modification of technique, this dropped significantly.²⁰ A more recent series reports 6 (27%) of 22 patients requiring elective surgery for soft tissue

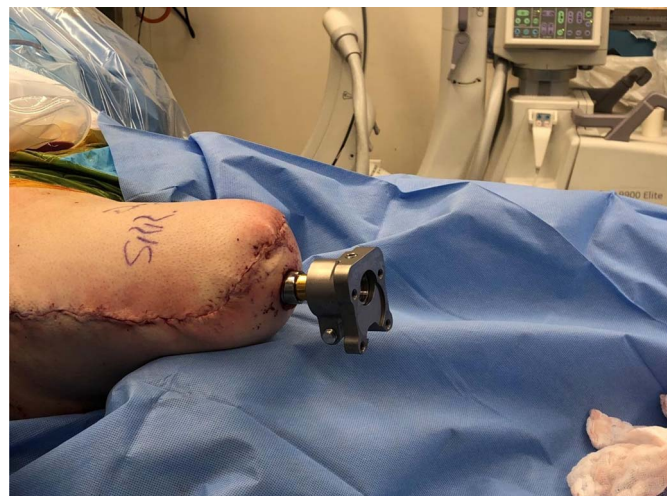

FIGURE 4. Immediate result after closure of soft tissues. [full color online](#)

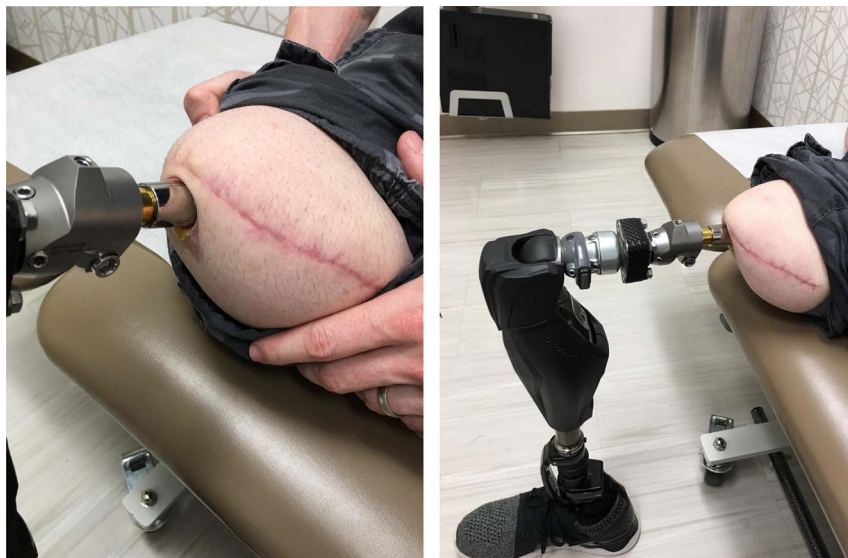

FIGURE 5. Typical appearance at postoperative follow-up visit. full color online

refashioning.¹⁵ The historically high rates of reoperation emphasize both the challenge and importance of the soft tissues for a successful reconstruction. An excessive skin envelope interferes with the prosthesis and leads to impingement, irritation, and shear forces that can compromise the viability of the soft tissues. Furthermore, the tissues will inevitably loosen and stretch as the patient ages. For this reason, we routinely extend the incision up the medial and lateral aspects of the limb to reduce the skin envelope dramatically at the time of implant placement. The surgeries described in this article allow for a 1-stage approach to soft tissue contouring and placement of an osseointegrated implant. Patients who present with a paucity of soft tissue or skin graft over an extremity stump do well with a percutaneous placement of the implant without any soft tissue recruitment, which underscores the importance of creating a tight, thin coverage of the implant bone interface. Our early results are encouraging, as there were no required soft tissue revisions to date.

CONCLUSIONS

The soft tissue envelope is an important consideration in patients with osseointegrated prostheses for lower extremity amputation and represents one of the most common causes for reoperation. We present our early experience and outcomes with soft tissue draping and incision planning at the time of implant placement and report no instances of revisional surgery for soft tissue redundancy nor any cases of delayed wound healing.

REFERENCES

- Ziegler-Graham K, MacKenzie EJ, Ephraim PL, et al. Estimating the prevalence of limb loss in the United States: 2005 to 2050. *Arch Phys Med Rehabil.* 2008;89:422–429.
- de Godoy JMP, Braile DM, Buzatto G, et al. Quality of life after amputation. *Psychol Health Med.* 2010;7:397–400.
- Ephraim PL, MacKenzie EJ, Wegener ST, et al. Environmental barriers experienced by amputees: the Craig Hospital inventory of environmental factors-short form. *Arch Phys Med Rehabil.* 2006;87:328–333.
- Fiedler G, Akins J, Cooper R, et al. Rehabilitation of people with lower-limb amputations. *Curr Phys Med Rehabil Rep.* 2014;2:263–272.
- Sinha R, van den Heuvel WJ, Arokiasamy P. Factors affecting quality of life in lower limb amputees. *Prosthet Orthot Int.* 2011;35:90–96.
- Dillingham TR, Pezzin LE, MacKenzie EJ, et al. Use and satisfaction with prosthetic devices among persons with trauma-related amputations: a long-term outcome study. *Am J Phys Med Rehabil.* 2001;80:563–571.
- Hagberg K, Branemark R. Consequences of non-vascular trans-femoral amputation: a survey of quality of life, prosthetic use and problems. *Prosthet Orthot Int.* 2001;25:186–194.
- Lyon CC, Kulkarni J, Zimerson E, et al. Skin disorders in amputees. *J Am Acad Dermatol.* 2000;42:501–507.
- Mohd Hawari N, Jawaid M, Md Tahir P, et al. Case study: survey of patient satisfaction with prosthesis quality and design among below-knee prosthetic leg socket users. *Disabil Rehabil Assist Technol.* 2017;12:868–874.
- Kark L, Simmons A. Patient satisfaction following lower-limb amputation: the role of gait deviation. *Prosthet Orthot Int.* 2011;35:225–233.
- Branemark PI, Hansson BO, Adell R, et al. Osseointegrated implants in the treatment of the edentulous jaw. Experience from a 10-year period. *Scand J Plast Reconstr Surg Suppl.* 1977;16:1–132.
- Branemark PI, Adell R, Breine U, et al. Intra-osseous anchorage of dental prostheses. I Experimental studies. *Scand J Plast Reconstr Surg.* 1969;3:81–100.
- Hebert JS, Rehani M, Stiegelmar R. Osseointegration for lower-limb amputation: a systematic review of clinical outcomes. *JBJS Rev.* 2017;5:e10.
- Li Y, Branemark R. Osseointegrated prostheses for rehabilitation following amputation: the pioneering Swedish model. *Unfallchirurg.* 2017;120:285–292.
- Al Muderis M, Lu W, Li JJ. Osseointegrated prosthetic limb for the treatment of lower limb amputations: experience and outcomes. *Unfallchirurg.* 2017;120:306–311.
- Muderis MA, Tetsworth K, Khemka A, et al. The Osseointegration Group of Australia Accelerated Protocol (OGAAP-1) for two-stage osseointegrated reconstruction of amputated limbs. *Bone Joint J.* 2016;98-B:952–960.
- Atallah R, Leijendekkers RA, Hoogbeem TJ, et al. Complications of bone-anchored prostheses for individuals with an extremity amputation: a systematic review. *PLoS One.* 2018;13:e0201821.
- Al Muderis M, Khemka A, Lord SJ, et al. Safety of osseointegrated implants for transfemoral amputees: a two-center prospective cohort study. *J Bone Joint Surg Am.* 2016;98:900–909.
- Aschoff HH, Kennon RE, Keggi JM, et al. Transcutaneous, distal femoral, intramedullary attachment for above-the-knee prostheses: an endo-exo device. *J Bone Joint Surg Am.* 2010;92:180–186.
- Juhnke DL, Beck JP, Jeyapalina S, et al. Fifteen years of experience with integral-leg-prosthesis: cohort study of artificial limb attachment system. *J Rehabil Res Dev.* 2015;52:407–420.
- Abdallah MN, Badran Z, Ciobanu O, et al. Strategies for optimizing the soft tissue seal around osseointegrated implants. *Adv Healthc Mater.* 2017;6.
- Mioton LM, Dumanian GA. Targeted muscle reinnervation and prosthetic rehabilitation after limb loss. *J Surg Oncol.* 2018;118:807–814.
- Hagberg K, Branemark R, Gunterberg B, et al. Osseointegrated trans-femoral amputation prostheses: prospective results of general and condition-specific quality of life in 18 patients at 2-year follow-up. *Prosthet Orthot Int.* 2008;32:29–41.
- Hagberg K, Branemark R, Hagg O. Questionnaire for Persons with a Transfemoral Amputation (Q-TFA): initial validity and reliability of a new outcome measure. *J Rehabil Res Dev.* 2004;41:695–706.
- Tillander J, Hagberg K, Berlin O, et al. Osteomyelitis risk in patients with transfemoral amputations treated with osseointegration prostheses. *Clin Orthop Relat Res.* 2017;475:3100–3108.