

# Humerus Lengthening With the PRECICE Internal Lengthening Nail

Anton M. Kurtz, MD\* and S. Robert Rozbruch, MD†

**Background:** Deformity and growth arrest of the humerus in children may result as sequelae of proximal humerus fractures and unicameral bone cysts, or as complications of their treatment. As approximately 80% of the growth of the humerus arises from the proximal physis, the resultant upper limb-length discrepancy can be substantial. Benefits to lengthening the shortened arm have been previously demonstrated with the use of external fixation devices. To our knowledge, no reports have been published on the use of intramedullary implants for this purpose.

**Methods:** A 15-year-old girl with humeral shortening secondary to proximal humeral growth disturbance following treatment for a unicameral bone cyst was treated with humeral osteoplasty and gradual lengthening with an off-label use of a fully implantable motorized intramedullary lengthening nail. A varus proximal humeral deformity and lateral starting point allowed for avoidance of the rotator cuff insertion.

**Results:** Humeral lengthening (5 cm) was achieved at 9 weeks, with bony union at 7 months, and hardware removal at 9½ months. Shoulder and elbow motion was maintained during and after treatment.

**Conclusions:** This is the first case report of humeral lengthening using a fully implantable motorized intramedullary lengthening nail. Although some technical limitations remain when compared with other methods, the procedure was well tolerated throughout the course of treatment.

**Level of Evidence:** Level IV—case report.

**Key Words:** growth arrest, humerus, lengthening, intramedullary, PRECICE

(*J Pediatr Orthop* 2017;37:e296–e300)

Deformity and growth arrest of the humerus in children may result as sequelae of proximal humerus fractures and unicameral bone cysts, or as complications

of their treatment.<sup>1–3</sup> Lengthening of the humerus has been accomplished with distraction osteogenesis using a variety of external fixators, including traditional monolateral, Ilizarov-type, and multiaxial correction frames.<sup>4–7</sup> Recently, highly reliable and accurate motorized intramedullary nails have become available for the femur and tibia.<sup>8</sup> Although no internal lengthening nail is currently indicated for use in the humerus, the lateral-entry femoral nail is compatible with the geometry and dimensions of the humerus in many cases. A search of PubMed yielded no reported cases in the literature of lengthening of the humerus with an intramedullary limb lengthening implant. Here, we present a case demonstrating lengthening of a shortened humerus in a 15-year-old girl using a fully implantable motorized intramedullary lengthening nail.

## A CASE REPORT

A 15-year-old girl presented for evaluation of shortening and deformity of the right arm. She had been treated for a bone cyst of the right proximal humerus at age 11 and the shortening had developed in the subsequent years. She denied any arm pain, but complained about the appearance of the arm and the effect of arm shortening on activities of daily living as well as occasional neck and upper back pain. Clinically the upper arm was 3 inches shorter on the right (Fig. 1). Range of motion of the right shoulder demonstrated full extension, forward flexion to 170 degrees, external rotation 90 degrees, and internal rotation to the midthoracic spine. Elbow range of motion was from full extension to 130 degrees with full pronosupination. The neurovascular exam was normal. Radiographs demonstrated 75-mm shortening of the right humerus with a midshaft, oblique plane deformity composed of 15-degree varus and 13-degree apex anterior. A varus deformity of the humeral head/neck was also present (Fig. 2). The patient and her parents were offered 2 surgical options: (1) humerus osteoplasty, application of external fixator, gradual correction of angular deformity, and complete correction of shortening over approximately 75 days with an anticipated time-in-frame of approximately 5 to 7 months; or (2) humerus osteoplasty, insertion of a fully implantable, motorized intramedullary nail, acute correction of angular deformity, and gradual lengthening to a maximum of 50 mm (due to the limitations of the nail). The nail system to be used was approved for lengthening of the tibia and femur and, as such, this indication represented an off-label use of the device. This was explained in detail to the patient and her parents. The patient and her family elected for the latter option. The varus deformity of the head and neck caused no pain or restriction in range of motion, but did allow access to the intramedullary canal without violation of the rotator cuff; we, therefore, chose to leave it uncorrected.

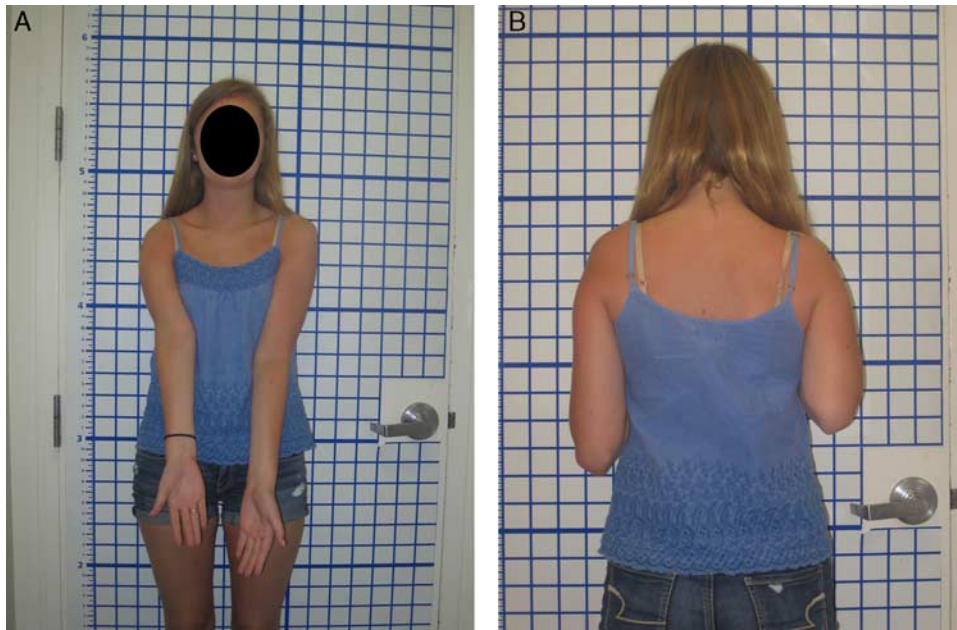From \*MaineOrtho, Portland, ME; and †The Limb Lengthening and Complex Reconstruction Service, Department of Orthopedic Surgery, Hospital for Special Surgery, Weill Medical College of Cornell University, New York, NY.

A.M.K. and S.R.R.: conception and design of the study and approval of the manuscript. A.M.K.: drafting the manuscript; S.R.R.: revising the manuscript.

Neither author received financial support for this study. S.R.R. serves as a paid consultant for Nuvasive. A.M.K. declares no conflicts of interest.

Reprints: Anton M. Kurtz, MD, MaineOrtho, 1601 Congress Street, Portland, ME 04102. E-mail: akurtz@maineortho.com.

Copyright © 2017 Wolters Kluwer Health, Inc. All rights reserved. DOI: 10.1097/BPO.0000000000000941

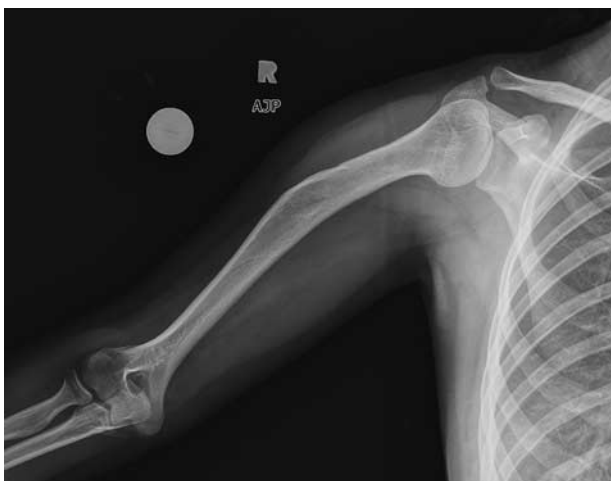

**FIGURE 1.** Preoperative (A) front and (B) back views demonstrating humeral shortening and full elbow range of motion.

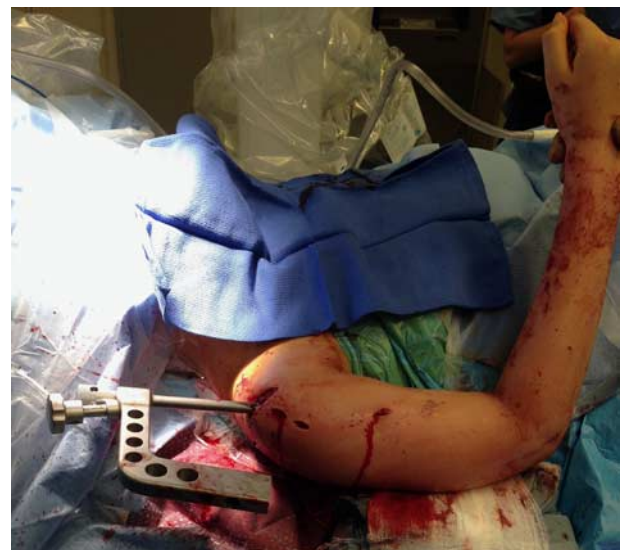### Description of Surgical Procedure

The patient was positioned supine on a radiolucent operating table with a bump under the right scapula. After the administration of regional anesthesia (supraclavicular block), the right arm was prepped and draped. The apex of the deformity was located at a point 105 mm distal to the proximal humerus. Multiple drill holes were made at this point through a 1-cm stab incision. A 3-cm incision was made at the antero-lateral border of the acromion to approach the proximal humerus. The starting point was localized with a Steinmann pin and noted to be just lateral to the rotator cuff insertion as a result of the varus head/neck deformity. The medullary canal was opened, a guidewire passed, and sequential reaming accomplished with cannulated reamers from 6 to 10 mm. The guidewire was removed, and a 215 mm × 8.5 mm lateral-entry

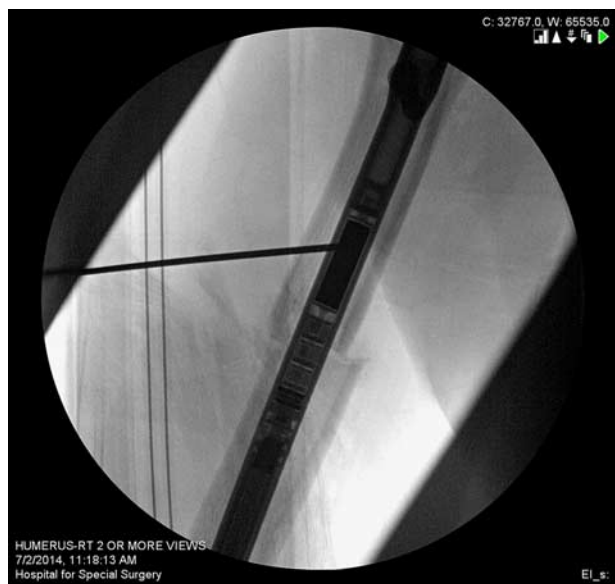femoral nail (PRECICE; Ellipse Technologies, Irvine, CA) was passed to a point just proximal to the previously drilled vent holes. The osteotomy was completed with an osteotome. The nail was advanced across the osteotomy acutely correcting the angular deformity (Fig. 3). The nail was locked proximally with two 5-mm screws using the guide arm. Distally, after localizing each distal locking hole, the image intensifier was moved (rather than the arm to avoid malrotation deformity) until a perfect circle was seen. The center of the hole was identified with a wire on the skin. The skin was incised and blunt dissection carried down to the bone to avoid injury to the neurovascular structures. Anteroposterior and lateral-medial locking bolts were



**FIGURE 2.** Preoperative anteroposterior radiograph demonstrating midshaft varus deformity and varus orientation of the humeral head/neck.



**FIGURE 3.** Intraoperative view of the arm after osteotomy, insertion of nail, and proximal locking.



**FIGURE 4.** Fluoroscopic identification of the internal magnet is used to mark the skin where the external remote controller is to be used.

placed. The position of the magnet was marked on the skin (Fig. 4). Wounds were irrigated and closed in layers.

### Postoperative Course

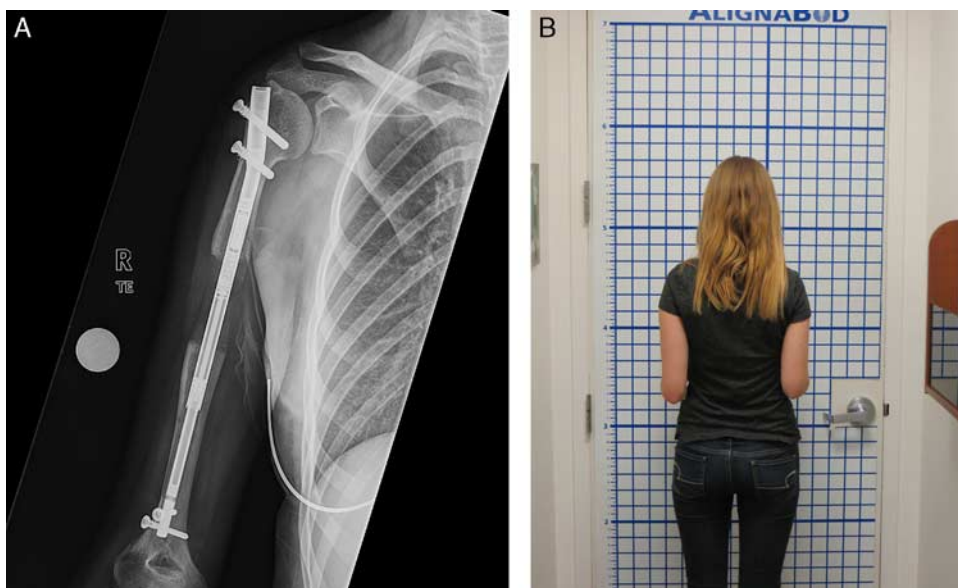
The patient began lengthening 0.25 mm 4 times a day on postoperative day 5. She returned to the office 2 weeks after surgery taking only Tylenol for pain control, having accomplished 10 mm of distraction. At 4 weeks postoperatively, some range of motion restriction was noted in the shoulder, and distraction was slowed to 0.25 mm 3 times a day. Our practice has been to check vitamin D levels in all patients preoperatively and to supplement accordingly. Patients are also given the option of

using a pulsed electromagnetic field bone stimulator (Biomet EBI Bone Healing System; Biomet, Warsaw, IN) for its theoretical benefit of enhancing bone formation and speeding up the healing, though evidence supporting its use is not robust.<sup>9,10</sup> In this case, both vitamin D supplementation and pulsed electromagnetic field bone stimulation was used for the first 3 months after surgery. At 9 weeks postoperatively, the patient had completed 5 cm of distraction and lengthening was stopped (Fig. 5). At 4 months postoperatively, the patient had full shoulder and elbow motion equal to her preoperative range. At 7 months postoperatively, the regenerate was completely healed. The nail was removed uneventfully at 9½ months from the original surgery (Fig. 6).

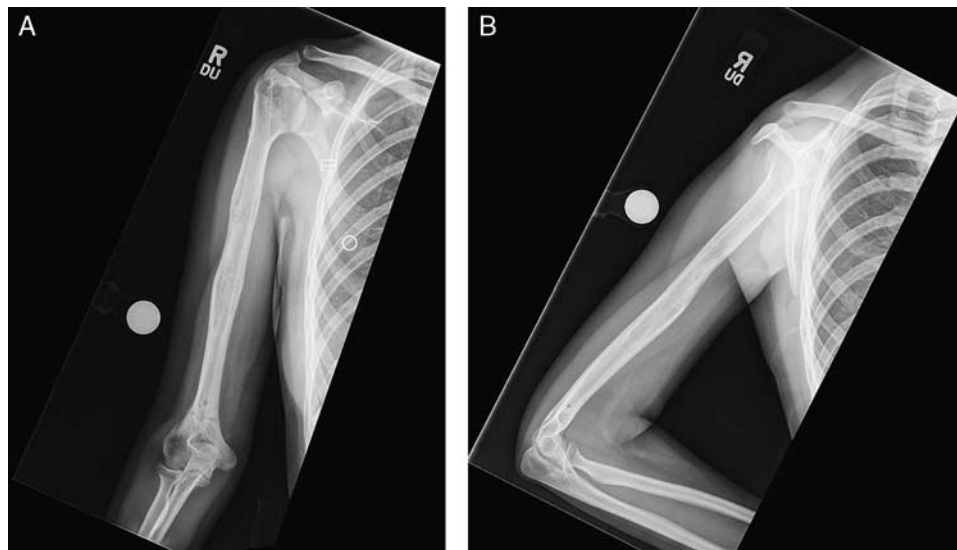
### DISCUSSION

Growth arrest of the proximal humeral physis may complicate 10% of proximal humeral unicameral bone cysts.<sup>3</sup> The precise etiology of injury to the physis is unknown.<sup>2</sup> As approximately 80% of the growth of the humerus arises from the proximal physis, the resultant upper limb-length discrepancy can be substantial.<sup>11</sup> A multiaxial correction monolateral frame, specifically, has been shown to be an effective tool in achieving greater function as measured by DASH scores and improved cosmesis in patients with shortening of the humerus.<sup>12,13</sup> Motorized intramedullary nails have allowed for improved adjacent joint range of motion during lengthening and eliminate the unsightly scars from pin sites encountered during lengthening with external fixators.<sup>8,14</sup>

Our case illustrates several benefits of this technique as applied to the humerus. The elimination of external fixation allows improved motion during the distraction and consolidation phases of treatment. Unsightly scars are also eliminated with this method. For substantial lengthenings, the time-in-frame may be 6 to 9 months.



**FIGURE 5.** A, Anteroposterior radiograph at the end of the distraction phase (9 wk postoperatively) demonstrating healthy regenerate and maintenance of alignment. B, Back view demonstrating final arm length.



**FIGURE 6.** Anteroposterior (A) and lateral (B) views after removal of hardware at 9½ months postoperatively.

The complete elimination of this factor is an obvious and dramatic advantage of internal fixation.

This technique is not without its limitations, however. The approach to intramedullary nailing of the humerus may involve incising and repairing the tendinous insertion of the supraspinatus, a potential source of pain and dysfunction.<sup>15</sup> In fact, multiple approaches to the starting point for antegrade humeral nailing have been described. These include the traditional anterolateral approach that violates the rotator cuff insertion, the rotator interval approach that exploits the interval between the supraspinatus and subscapularis, a modified extra-articular, extrarotator cuff approach below the greater tuberosity crest, and a superomedial Neviaser portal approach through the supraspinatus muscle belly.<sup>16–18</sup> Retrograde nailing has been described as well, but suffers from numerous risks.<sup>19</sup> The point at which the humerus is opened depends on nail design.

In cases with shortening alone, without coronal or sagittal deformity, the nail trajectory is straight and the choice of osteotomy site is less important. In this case, the osteotomy was placed at the apex of the deformity to allow for a nail-mediated correction as the device was passed. Techniques that may aid deformity correction in the femur or tibia, such as fragment-specific eccentric reaming or placement of blocking (Poller) screws, are not as important or as easily used in the humerus which is dominated by the diaphysis. The most obvious limitations arise from the implant itself. At present, the shortest nails available are 160 mm (tibial) and 170 mm (femoral) in length. Any humeral canal shorter than this distance, therefore, is beyond the capability of this technique. These sizes are already shorter than those available at the time this case was performed. In addition, for nails appropriately sized for typical cases of humeral shortening, the current generation of telescopic nails allow a maximum stroke of 3 or 5 cm, depending on nail length, thus any discrepancy > 50 mm (as was the case for our patient) will not be fully resolved with this method.

We feel this technique will emerge as an important advance in the treatment of humeral shortening. Humerus-specific nail designs may be able to address some of the implant-related limitations in the future.

## REFERENCES

1. Popkin CA, Levine WN, Ahmad CS. Evaluation and management of pediatric proximal humerus fractures. *J Am Acad Orthop Surg.* 2015;23:77–86.
2. Violas P, Salmeron F, Chapuis M, et al. Simple bone cysts of the proximal humerus complicated with growth arrest. *Acta Orthop Belg.* 2004;70:166–170.
3. Stanton RP, Abdel-Mota'al MM. Growth arrest resulting from unicameral bone cyst. *J Pediatr Orthop.* 1998;18:198–201.
4. McLawhorn AS, Sherman SL, Blyakher A, et al. Humeral lengthening and deformity correction with the multiaxial correction system. *J Pediatr Orthop B.* 2011;20:111–116.
5. Hosny GA. Unilateral humeral lengthening in children and adolescents. *J Pediatr Orthop B.* 2005;14:439–443.
6. Lee FY-I, Schoeb JS, Yu J, et al. Operative lengthening of the humerus: indications, benefits, and complications. *J Pediatr Orthop.* 2005;25:613–616.
7. Cattaneo R, Villa A, Catagni MA, et al. Lengthening of the humerus using the Ilizarov technique. Description of the method and report of 43 cases. *Clin Orthop Relat Res.* 1990;250:117–124.
8. Rozbruch SR, Birch JG, Dahl MT, et al. Motorized intramedullary nail for management of limb-length discrepancy and deformity. *J Am Acad Orthop Surg.* 2014;22:403–409.
9. Eyres KS, Saleh M, Kanis JA. Effect of pulsed electromagnetic fields on bone formation and bone loss during limb lengthening. *Bone.* 1996;18:505–509.
10. Luna Gonzalez F, Lopez Arévalo R, Meschian Coretti S, et al. Pulsed electromagnetic stimulation of regenerate bone in lengthening procedures. *Acta Orthop Belg.* 2005;71:571–576.
11. Pritchett JW. Growth plate activity in the upper extremity. *Clin Orthop Relat Res.* 1991;268:235–242.
12. Pawar AY, McCoy TH, Fragomen AT, et al. Does humeral lengthening with a monolateral frame improve function? *Clin Orthop Relat Res.* 2013;471:277–283.
13. Tellisi N, Ilizarov S, Fragomen AT, et al. Humeral lengthening and deformity correction in Ollier's disease: distraction osteogenesis with a multiaxial correction frame. *J Pediatr Orthop B.* 2008;17:152–157.

14. Kirane YM, Fragomen AT, Rozbruch SR. Precision of the PRECICE internal bone lengthening nail. *Clin Orthop Relat Res*. 2014;472:3869–3878.
15. Ajmal M, O'Sullivan M, McCabe J, et al. Antegrade locked intramedullary nailing in humeral shaft fractures. *Injury*. 2001;32:692–694.
16. Park J-Y, Pandher DS, Chun J-Y, et al. Antegrade humeral nailing through the rotator cuff interval: a new entry portal. *J Orthop Trauma*. 2008;22:419–425.
17. Dimakopoulos P, Papadopoulos AX, Papas M, et al. Modified extra rotator-cuff entry point in antegrade humeral nailing. *Arch Orthop Trauma Surg*. 2005;125:27–32.
18. Dilisio MF, Fitzgerald RE, Miller ET. Extended Neviaser portal approach to antegrade humeral nailing. *Orthopedics*. 2013;36:e244–e248.
19. Rommens PM, Verbruggen J, Broos PL. Retrograde locked nailing of humeral shaft fractures. A review of 39 patients. *J Bone Joint Surg Br*. 1995;77:84–89.